


PATIENT

Gibson Hannah

SPECIES

Canine

BREED

Lab Mix

SEX

Male Neutered

AGE

5 years

WEIGHT

49.4lbs

INTERPRETED BY

 Maggie Machen Lamy,
 DVM DACVIM
 (Cardiology)

IMAGING PERFORMED BY

Crystal Hill, RVT

HOSPITAL NAME

 Queensway
 Veterinary Hospital

REFERRING VET

Dr. Saad

INVOICE

29897

DATE

3/28/23

PRESENTING CLINICAL SIGNS

History: Gibson was seen first on March 1st with temp of 40C and transparent nasal discharge, was sent home on Meloxicam then he came back on March 10th with temp of 40C as well and crusty unilateral nasal discharge and bloody diarrhea occasionally, BW showed leukocytosis, Neutrophilia and Monocytosis, X rays non-significant, was sent home on Doxycycline, Metronidazole, Meloxicam and Cerenia. Gibson was last seen March 21st had irregular arrhythmia and pulse deficits, Temp 39.5C no discharge and CBC looked WNL. Now on Amoxi Clav.

*Patient was notably stressed throughout the ECG.

ELECTROCARDIOGRAPHIC FINDINGS *Note: Single lead ECGs are evaluated as a rhythm strip. Morphology/MEA cannot be definitively commented on.

A single lead ECG is available; 50mm/s, 20mm/mV. The average heart rate is 170bpm (range 50-230bpm) with periods of significant tachycardia. Significant motion artifact noted throughout; however, no obvious premature beats are appreciated. ECG diagnosis: Normal sinus rhythm with significant sinus tachycardia.

ECHOCARDIOGRAM FINDINGS

2D, m-mode, color flow and doppler imaging is available. Normal mitral valve leaflets with no prolapse into the left atrial lumen. No obvious mitral regurgitation with a normal left atrial dimension. Normal LV diameter with adequate myocardial function (for this signalment). The tricuspid valve appears normal with no tricuspid regurgitation. Normal right atrial and ventricular diameter and morphology indicating no overt evidence of pulmonary arterial hypertension. The pulmonic and aortic valves are normal in morphology and mobility. Normal pulmonic and aortic outflow velocities with laminar flow. No obvious aortic or pulmonic insufficiency. No pericardial or pleural effusion noted. No obvious cardiac masses.

CARDIAC CHART

CANINE CARDIAC PARAMETERS	MR VMAX (m/s)	TR VMAX (m/s)	LA/AO (Boon method)	LA/AO (Heart Base; Swe)	FS (%)	EF (%)	EPSS (cm)
NORMAL PARAMETER	4.5-5.5	<2.7	1.3	<1.6	28-40	40-100	<0.6
PATIENT	NA	NA	1.4	1.2	27	50	0.5
CANINE CARDIAC PARAMETERS	HR (BPM)	AV VMAX (m/s)	PV MAX (m/s)	BODY WEIGHT (kg)	LA 2D short axis Base view (cm)	LVIDd Avg; 2D and m-mode short axis (cm)	LVIDs Avg; 2D and m-mode short axis (cm)
NORMAL PARAMETER	50-100	0.7-1.7	0.7-1.6	BELOW	BELOW	BELOW	BELOW
PATIENT	240	0.7	1.0	22.4	2.6	4.1	3.0
*Normal chamber parameters expressed as a mean value (SD)				3	1.27 (5.3)	2.46 (2.46)	1.36 (5.5)
BODY WEIGHT DEPENDENT PARAMETERS				5	1.40 (4.5)	2.74 (5.2)	1.60 (4.7)
*Note: All measurements based upon multi-modal images and methods. An average value is reported.				10	1.50 (3.8)	3.27 (3.5)	2.06 (3.1)
				15	1.83 (2.0)	3.71 (2.4)	2.43 (2.1)
				20	2.02 (1.9)	4.14 (2.2)	2.80 (2.0)
				25	2.18 (2.4)	4.48 (2.9)	3.10 (2.5)
				30	2.33 (3.3)	4.83 (3.9)	3.39 (3.4)

Adapted from June Boon, Veterinary Echocardiography, 1998
 Rishniw M and Hollis NE, J Vet Intern Med 2000; 14:429-435



PATIENT

Gibson Hannah

Hansson et al, Vet Rad and Ultrasound 2002	35	2.48 (4.3)	5.17 (5.0)	3.69 (4.5)
Bonagura et al. Echocardiography: principles of interpretation, Vet Clin North Am 15:1177, 1995	40	2.62 (5.2)	5.48 (6.1)	3.96 (5.4)
	50	2.88 (7.1)	6.07 (8.3)	4.46 (7.4)

SPECIES

Canine

INTERPRETATION OF THE FINDINGS & FURTHER RECOMMENDATIONS

Overtly normal cardiac dimensions and function, with no obvious dysfunction or dilation of the left heart. No significant valvular leaks are visualized, and no evidence of pulmonary hypertension.

BREED

Lab Mix

The ECG is largely unremarkable with a sinus rhythm. Periods of sinus tachycardia are appreciated, up to 230bpm; however, the warm-up and cool-down periods are transitional. The patient was also stressed during the recording, which is the likely cause. No obvious dysrhythmias were observed. If this does not much what was heard on exam, a longer tracing or potentially a holter monitor may be warranted.

SEX

Male Neutered

AGE

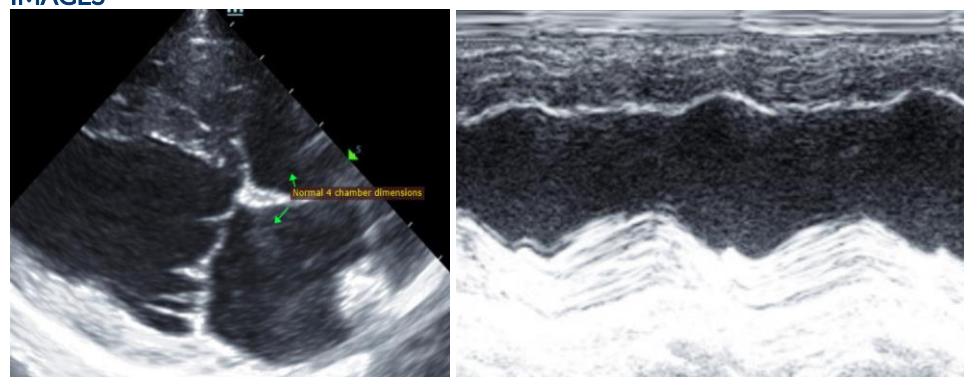
5 years

Monitor for development of a heart murmur, cough, labored breathing, exercise intolerance or collapse episodes.

WEIGHT

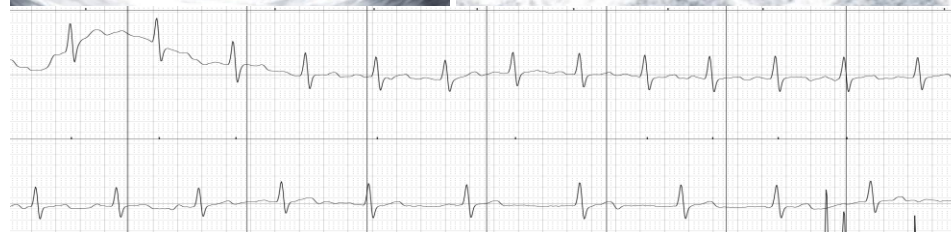
49.4lbs

IMAGES



INTERPRETED BY

Maggie Machen Lamy,
DVM DACVIM
(Cardiology)



IMAGING PERFORMED BY

Crystal Hill, RVT

HOSPITAL NAME

Queensway
Veterinary Hospital

REFERRING VET

Dr. Saad

INVOICE

29897

DATE

3/28/23



PATIENT

Gibson Hannah

The information and recommendations provided are based on the images presented by the referring veterinarian. No evaluation can be communicated regarding pathology that was not visible in the image/video clips provided.

SPECIES

Canine

Thank you for this referral. This report was generated using transcription software, and minor dictation errors may be present. If the clinical or image interpretation does not parallel your findings or if I can be of any further assistance, please contact me.

BREED

Lab Mix

Maggie Machen Lamy, DVM
Diplomate of the American College of Veterinary Internal Medicine (Cardiology)
info@sonopath.com

SEX

Male Neutered

AGE

5 years

WEIGHT

49.4lbs

INTERPRETED BY

Maggie Machen Lamy,
DVM DACVIM
(Cardiology)

**IMAGING
PERFORMED BY**

Crystal Hill, RVT

HOSPITAL NAME

Queensway
Veterinary Hospital

REFERRING VET

Dr. Saad

INVOICE

29897

DATE

3/28/23